



Talonavicular Subchondral Fracture Healing on MRI Post Single Autologous Fat-Derived Expanded Mesenchymal Stem Cell Therapy: A Case Report

Case Report

Advances in Orthopedics and Sports Medicine
ISSN 2641-6859

AOASM-181

Hassan Mubark*

Rheumatologist, Institution: Auckland Regenerative Clinic, Ormiston Specialist Centre, 125 Ormiston Road, Flat Bush, Auckland 2019, New Zealand

Received Date: April 05, 2023; **Accepted Date:** April 10, 2023; **Published Date:** April 17, 2023;

***Corresponding author:** Hassan Mubark. Rheumatologist, Institution: Auckland Regenerative Clinic, Ormiston Specialist Centre, 125 Ormiston Road, Flat Bush, Auckland 2019, New Zealand, Ph: +64 9 2713305 Fax: +64 9 2770769, Mobile: +64 21843513 Email: drhassnmubark@gmail.com

Abstract

A talonavicular fracture is a form of foot fracture that involves the talus and the navicular bones. This sort of fracture is typically triggered by a sudden injury.

Management of talonavicular fracture commonly involves immobilizing the foot and ankle with a cast or brace to allow the bones to heal properly. In some instances, surgery could be necessary to realign the bones to ensure appropriate healing.

This article presents a middle-aged female, a professional Pilates teacher who suffered an injury to her left talonavicular joint (TNJ) which led to chondral injury and subchondral talar fracture, with an accelerated traumatic TNJ osteoarthritis. She had significant symptoms that interfered with her daily activities and work. She failed anti-inflammatory medicine, intra-articular steroid, and platelet-rich plasma (PRP) combined with hyaluronic acid injections. She was offered surgical debridement of cartilage and fusion of the TNJ, instead, she elected experimental intra-articular autologous fat-derived expanded mesenchymal (MSCs) combined with PRP. She reported dramatic clinical improvement two months post-therapy, and a gradual return to her loved work with an MRI six months post-treatment revealing bone remodeling and complete healing of the fracture with associated articular and

peri-articular high signals hypothesizing inflammatory healing response rather than the pathological inflammation given she had significant improvement of her clinical presentation and function.

This case demonstrates the use of MSC therapy combined with PRP as a non-surgical approach in traumatic chondral injuries and subchondral fracture letting joint fusion as a last resort. Of note, she failed the intra-articular trial of PRP combined with hyaluronic acid while a positive result was achieved when expanded MSCs were combined with PRP as a superior regenerative therapy. We need a large randomized controlled trial to confirm our findings.

Keywords: Bone; Fracture; Mesenchymal Stem Cells; PRP; Remodeling; Subchondral; Talonavicular

Introduction

A subchondral fracture is a type of fracture that arises in the subchondral bone. This sort of fracture can occur because of a traumatic injury, such as a fall or sports-related injury.

Subchondral traumatic fractures are most seen in the knee joint and are less common in other joints including the ankle, hip, and shoulder joints.

Healing of this type of injury is a compound regenerative process with the contribution of abundant cell types including inflammatory, progenitor, endothelial, and hematopoietic cells together with growth factors for example TGF- β [1, 2].

Management for this type of fracture typically involves rest, immobilization of the joint, and anti-inflammatory and pain medicines. The next step is invasive surgical procedures that require a natural or synthetic bone graft with subsequent risks of complications [3, 4, 5].

Case Report

A middle-aged female works as a professional Pilates teacher and trainer. She is normally fit and healthy, she rolled her left ankle in May 2021 with subsequent pain, swelling, and

stiffness with signs of tenderness and reduced range of motion of the talonavicular joint (TNJ). An ultrasound scan (USS) in July 2021 showed significant synovitis of the TNJ with associated joint effusion. She failed to respond to conservative management with Brufen and an ankle brace. In September 2021 X-ray showed no fracture line, normal joint alignment, subchondral sclerosis, and partial loss of joint space, consistent with mild TNJ osteoarthritis. She was referred to the orthopaedic surgeon, and a repeat USS in Oct 2021 showed quite marked synovial thickening and joint fluid at the TNJ, she had USS-guided intra-articular triamcinolone 40 MG mixed with a local anaesthetic to control the synovitis. Despite those measures, her symptoms worsened, and an MRI scan in Jan 2022, showed extensive chondral loss and marked associated synovitis within the TNJ, accompanied by undisplaced subchondral fracture at the talar head articular surface as in **Figure 1**.

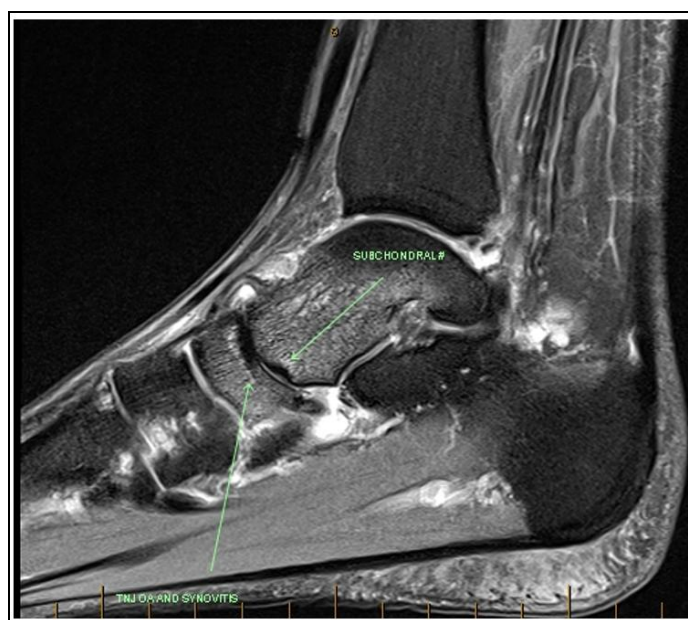


Figure 1: Sagittal FS T2 MRI demonstrating subchondral fracture at the talonavicular joint (TNJ).

The orthopaedic surgeon discussed with her having an experimental trial of the combination of platelet-rich plasma (PRP) with hyaluronic acid under USS guidance, this was performed in May 2022, this has failed and left with the only option of TNJ fusion; which consists of removing the remnants of the cartilage of the joint, re-aligning it and fixing it with a plate and screws plus bone graft, the resultant stiffening of the midfoot and the hindfoot, she would need to be six weeks non-weight bearing and then six weeks protected weight bearing. The patient was worried about losing her joint movement and her job as a Pilates teacher and ultimately with the consequence of financial and psychological burdens. She elected an experimental trial of expanded mesenchymal stem cell (MSC) therapy as a last hope before proceeding to joint fusion. We performed the fat harvest then the stromal vascular fraction (SVF) was sent to the specialized biologic lab for

purification, sterilization, and expansion to a dose of 75×10^6 divided into three syringes. We prepared the PRP using ACD-A tubes and centrifuged it over nine minutes; a total volume of 6 MLS (mixture of MSCs and PRP) was engrafted through multiple directions to cover the TNJ, fracture site, and the surrounding soft tissues using Sonosite USS-guided L38, 10-5 MHZ transducer.

We asked her to use regular moonboot for two weeks and crutches followed by another two weeks of gentle use of the foot. She was followed two months after the stem cell therapy and reported significant improvement in pain score, stiffness, and improvement of TNJ range of motion with a gradual return to work. She progressed well with a repeat MRI post-therapy six months post the MSC therapy revealed full healing of the TNJ subchondral fracture with bone remodelling, also noted high

T2 signals in the joint and the surrounding bones presumed the

inflammatory healing response as in **Figure 2**.

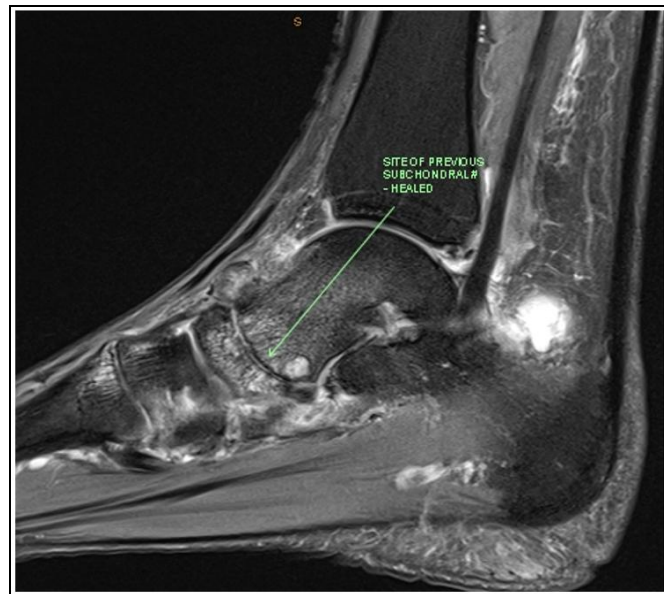


Figure 2: Sagittal FS T2 MRI post stem cell therapy showing remodeling and complete healing of the subchondral fracture.

She remained with occasional niggles of pain and rare use of Brufen, but we expect this will recover with time given she has clinical improvement and radiological healing of the subchondral fracture. Our intention is to perform MRI series to see the status of the chondral loss as that process is slow.

Discussion

There is no cure for TNJ osteoarthritis, particularly when associated with subchondral fracture, this process is usually progressive and eventuates into surgical joint fusion. The issue with joint fusion is the correlated stiffness in the mid and hind foot which will lead to loss of function and finally affect the physical and sports life.

MSC therapy is fascinating and promising science as it can provide appropriate cellular signals to boost tissue regeneration with an exceptional anti-inflammatory effect. MSCs are presently being investigated in numerous research facilities and clinical observers to verify efficacy and safety [6, 7]. In addition, randomized controlled trials suggested the positive outcome of MSCs in osteoarthritis [8]. Bone regeneration is a method in which osteoclasts and osteoblasts are firmly involved [9]. Notwithstanding the spontaneous regeneration perspective, there are various distinctive explanations such as bone defect size and infection that cause damaged bone not to be capable to repair itself [10].

Our patient had superior clinical and radiological outcomes due to the anabolic effects of combined expanded MSCs with PRP while failing to respond to anti-inflammatory medicine, brace, intra-articular steroid, and combined PRP with hyaluronic acid, an MRI scan showed complete healing

of the subchondral fracture, additionally, we noted high signals inside and around the joint suggestive of the inflammatory signalling healing response rather than active pathologic inflammation as similar findings were noted in the literature [11,12]. She did not require fusion of the joint and she returned to her loved job with good functional ability suggestive of the successful outcome of the MSC therapy.

Conclusion

We hypothesize the use of expanded mesenchymal stem cells combined with platelet-rich plasma has resulted in the resolution of subchondral fracture with dramatic symptomatic relief, and improvement of her joint mobility and quality of life. The mesenchymal stem cell therapy saved her from complex surgical intervention. However, we need to confirm those findings are consistent in broad randomized controlled trials.

Competing Interests

The author has declared that no competing interests exist.

References

1. Kolar P, Schmidt-Bleck K, Schell H, Gaber T, Toben D, et al. (2010). The early fracture hematoma and its potential role in fracture healing. *Tissue Eng B Rev*; 16:427-34.
2. Ho-Shui-Ling A, Bolander J, Rustom LE, Johnson AW, Luyten FP, et al. (2018). Bone regeneration strategies: engineered scaffolds, bioactive molecules and stem cells current stage and future perspectives. *Biomaterials*.

3. Wang W, Yeung KW. Bone grafts and biomaterials substitutes for bone defect repair: a review. *Bioactive Materials*. 2017; 2:224-47.
4. Fernandez de Grado G, Keller L, Idoux-Gillet Y, Wagner Q, Musset A-M, Benkirane-Jessel N, Bornert F, Offner D: Bone substitutes: a review of their characteristics, clinical use, and perspectives for large bone defects management. *J Tissue Eng* 2018, 9:2041731418776819.
5. Campana V, Milano G, Pagano E, Barba M, Cicione C, et al. (2014). substitutes in orthopaedic surgery: from basic science to clinical practice. *J Mater Sci Mater Med*. 25:2445-61.
6. Brown MH, Scholes C, Hafsi K, Marenah M, Li J, et al. (2019) Efficacy and safety of culture-expanded, mesenchymal stem/stromal cells for the treatment of knee osteoarthritis: a systematic review. *J Orthop Surg Res* 14:34.
7. Centeno CJ, Al-Sayegh H, Freeman MD, Smith J, Murrell WD, et al. (2018) A multi-center analysis of adverse events among two thousand, three hundred and seventy-two adult patients undergoing adult autologous stem cell therapy for orthopaedic conditions. *Int Orthop* 40:1755-1765.
8. Han X, Yang B, Zou F, Sun J (2020) Clinical therapeutic efficacy of mesenchymal stem cells derived from adipose or bone marrow for knee osteoarthritis: a meta-analysis of randomized controlled trials. *J Comp Eff Res* 9:361-374.
9. Greg Hutchings, Lisa Moncrieff, Claudia Dompe, et al. (2020). Bone Regeneration, Reconstruction and Use of Osteogenic Cells; from Basic Knowledge, Animal Models to Clinical Trials. *J Clin Med*. Jan; 9(1):139.
10. Lichti P, Pape H, Pufe T, Kobbe P, Fischer H. Scaffolds for bone healing: concepts, materials and evidence. *Injury*. 2011; 42:569-73.
11. Mubark H. Successful treatment with autologous mesenchymal stem cells therapy for muscle wasting postsurgical repair of achilles tendon: a case report. *Adv Ortho and Sprts Med: AOASM*. 2021;145.
12. Jiankai Fang, Chao Feng, Wangwang Chen, Pengbo Hou, Zhanhong Liu, Muqiu Zuo, Yuyi Han, Chenchang Xu, Gerry Melino, Alexei Verkhatsky, Ying Wang, Changshun Shao & Yufang Shi. Redressing the interactions between stem cells and immune system in tissue regeneration. *Biology Direct* volume 16, Article number: 18 (2021).

Citation: Mubark H (2023) Talonavicular Subchondral Fracture Healing on MRI Post Single Autologous Fat-Derived Expanded Mesenchymal Stem Cell Therapy: A Case Report. *Adv Pub Health Com Trop Med: AOASM-181*.